Journal of Hepatology 2000; 33: 926–932
Printed in Denmark · All rights reserved
Munksgaard · Copenhagen

Copyright © European Association for the Study of the Liver 2000

Journal of Hepatology
ISSN 0168-8278

Covalent adducts of proteins with acetaldehyde in the liver as a result of acetaldehyde administration in drinking water

Kalle Jokelainen[1], Seppo Parkkila[2], Mikko Salaspuro[1] and Onni Niemelä[2,3]

[1]*Alcohol Research Unit, Helsinki University Hospital, Helsinki,*
and [2]Department of Clinical Chemistry and Anatomy, University of Oulu and [3]EP Central Hospital Laboratory, Seinäjoki, Finland

Background/Aims: **Acetaldehyde, the first metabolic product of ethanol, has been suggested to be responsible for several adverse effects of ethanol through its ability to form covalent adducts with proteins and cellular constituents. It has recently been suggested that acetaldehyde derived from microbial ethanol oxidation in the gut could also contribute to the effects of ethanol in the liver. The present work aimed to examine whether modification of proteins by acetaldehyde occurs in rat liver as a result of acetaldehyde administration in drinking water.**

Methods: **Rats were fed with either 0.7% acetaldehyde (n=10) or water (n=10) for 11 weeks. At the end of the feeding period, liver specimens were processed for immunohistochemistry for protein adducts with acetaldehyde and for hepatic cell type-specific protein markers.**

Results: **Mild fatty change was found in the liver of the acetaldehyde-treated animals but not in the control animals. Immunohistochemical stainings for acetaldehyde adducts revealed intensive positive staining for acetaldehyde adducts in eight (80%) of the animals fed with acetaldehyde. The adducts were predominantly perivenular, although positive staining also occurred along the sinusoids and in the periportal area. Double immunofluorescence staining experiments revealed that hepatocytes were the primary targets of acetaldehyde adduct deposition, although stellate cells and Kupffer cells also showed weak positive reactions.**

Conclusions: **The present data indicate that acetaldehyde-protein adducts are formed in the liver of animals following acetaldehyde administration in drinking water, which may contribute to the hepatotoxicity of extrahepatic acetaldehyde. These findings should be implicated in studies on the extrahepatic pathways of ethanol oxidation.**

Key words: **Ethanol metabolism; Immunohistochemistry; Liver disease.**

THE MAIN metabolite of ethanol is acetaldehyde, which has been shown to accumulate in the liver and blood as a result of excessive alcohol consumption (1). Through its ability to generate covalent adducts with several target proteins, acetaldehyde has been suggested to play a pivotal role in the pathogenesis of alcohol-induced liver disease (1–3). Recent studies in both human alcoholics and experimental animals fed with ethanol have demonstrated the formation of hepatic acetaldehyde-protein adducts *in vivo* together with the occurrence of histopathological features of alcoholic liver disease (4–8).

It has recently been shown that marked amounts of acetaldehyde may be generated through extrahepatic metabolism of ethanol (9–11). An animal model recently developed by Salaspuro and co-workers has provided a new tool for examining the hepatotoxicity of extrahepatic acetaldehyde (12,13). In this model, acetaldehyde administered in drinking water has been shown to be readily absorbed in the gastrointestinal tract and to reach the liver via the portal circulation, inducing histopathological changes (12). However, neither the formation of acetaldehyde-derived hepatic protein adducts following the administration of acetaldehyde via the digestive tract nor their possible association with the appearance of liver lesions has been explored.

Received 21 July; revised 17 December 1999; accepted 17 February 2000

Correspondence: Onni Niemelä, EP Central Hospital Laboratory, FIN-60220 Seinäjoki, Finland.
Tel: 358 6 415 4719. Fax: 358 6 415 4924.
e-mail: onni.niemela@epshp.fi

PM3006739375

Source: https://www.industrydocuments.ucsf.edu/docs/psnx0001

To clarify the role of extrahepatic acetaldehyde in the pathogenesis of liver disease, we examined whether acetaldehyde administered in drinking water induced acetaldehyde-derived protein adducts and how they correlated with histopathological changes in the liver. The localisation of acetaldehyde adducts in the liver was also characterised in double immunofluorescence experiments using antibodies to Kupffer cells and stellate cells.

Materials and Methods

Animal model

The present animal protocol has been described in detail previously (9,12). In brief, twenty 10-week-old male Wistar rats (weight 430–385 g) were housed in plastic cages under conventional conditions. The room temperature was maintained at 22±2°C with a 12-h light/dark cycle. All rats had free access to a standard diet (Altromin 1324-pellets, Altromin, Lage, Germany) containing 19% proteins, 4% fat, 6% fibre, 7% ash, 13.5% moisture, and 50.5% nitrogen-free extracts.

Rats were fed either with acetaldehyde (0.7%) or with water. In order to maintain the appropriate concentration of acetaldehyde, the drinking acetaldehyde-containing solutions in each bottle were changed simultaneously every second–third day. The concentrations of acetaldehyde in the replaced bottles were measured by head-space chromatography, as previously described (14), and found to be almost unchanged.

The animals were weighed weekly and their general condition and behaviour were recorded, as well as their daily intake of liquid. All the experiments described in the present work were carried out in compliance with institutional guidelines and were in full compliance with the Public Health Service *Guide for the Care and Use of Laboratory Animals.*

Liver histology

Rats underwent biopsy and autopsy after 11 weeks of acetaldehyde exposure. The animals were anaesthetised with pentobarbital sodium (Orion-Farmos, Finland). After opening the abdomen, the liver was removed and weighed. Liver samples were fixed with 10% phosphate-buffered formalin, embedded in paraffin, and stained with haematoxylin and eosin (H & E) to assess histology. In addition, for the detection of fat, Oil Red O staining was performed on frozen sections.

The degree of fatty change in the liver specimens was assessed blindly by morphometric analysis. The number of hepatocytes occupied by fat was estimated by determining an 'area fraction' at high magnification (×400) in five periportal and five pericentral areas in all rats. An ocular grid composed of 100 small squares was used. The 'area fraction' was determined by counting the number of points falling on hepatocytes with fatty vacuoles divided by the total number of points falling on all hepatocytes in the area of the grid. The measurements were carried out on H & E sections.

Preparation of acetaldehyde-derived conjugates

Preparation of acetaldehyde-derived conjugates was carried out essentially as described previously (2,4). Acetaldehyde was added to aliquots of the freshly prepared bovine serum albumin solution, both containing 12 mg protein/ml in phosphate buffered saline (PBS), to obtain a final acetaldehyde concentration of 10 mM. The mixture was allowed to react under tightly sealed containers at +4°C overnight (18 h). Protein adducts were reduced by addition of sodium cyanoborohydride to 10 mM and mixing for 5 h at +4°C. Prior to use in immunisations, all protein solutions were dialysed twice against PBS at +4°C and stored in small aliquots for single use at −70°C.

Antibodies

Polyclonal anti-acetaldehyde adduct antibodies were raised in rabbits by subcutaneous injections of acetaldehyde-bovine serum albumin conjugate (1 mg) prepared as described above. Three booster injections were given with 500 μg of the conjugate at 3-week intervals. The animals were bled at 2-week intervals after the second immunisation and the anti-acetaldehyde adduct serum was cross-adsorbed on human plasma protein-acetaldehyde conjugate linked to Sepharose 4B (Pharmacia Fine Chemicals, Uppsala, Sweden).

The monoclonal anti-monocytes/macrophages, clone ED-1, antibody was from Chemicon, Temecula, CA, USA. Monoclonal anti-desmin, clone DE-U-10 and monoclonal anti-α-smooth muscle actin, clone 1A4 were products of Sigma (St Louis, Mo, USA).

Immunohistochemical methods

Liver biopsy specimens were fixed in 4% neutral-buffered formaldehyde, dehydrated, and embedded in paraffin. For immunohistochemistry the sections were stained by the biotin-streptavidin complex method, employing the following steps: (A) deparaffinization of the tissue sections, (B) pre-treatment of the sections with 3% hydrogen peroxide for 5 min followed by rinsing in PBS for 5 min, (C) pre-treatment with undiluted cow colostral whey (Hi-Col, Oulu, Finland) for 40 min to block non-specific binding followed by rinsing in PBS, (D) incubation for 1 h with a 1:200 dilution of the primary rabbit antiserum in 1% BSA-PBS followed by washing in PBS three times for 10 min, (E) treatment with cow colostral whey for 40 min followed by rinsing in PBS, (F) incubation for 1 h with biotinylated affinity-purified goat immunoglobulins to rabbit immunoglobulins (Dakopatts, Glostrup, Denmark), diluted 1:300 in 1% BSA-PBS followed by washing in PBS three times for 10 min, (G) treatment with cow colostral whey for 5 min, (H) incubation for 30 min with a 1:600 dilution of peroxidase-conjugated streptavidin in PBS and washing in PBS three times for 5 min, and (I) incubation for 3 min in DAB (9 mg DAB in 15 ml PBS plus 10 μl of 30% hydrogen peroxide). All incubations and washings were carried out at room temperature, and the sections were mounted in Permount (Fisher Scientific, Fair Lawn, NJ, USA). Intensity of the staining was scored on a scale of 0 to 3+ independently by two of the investigators (ON, SP) in a blinded fashion as follows: 0, no reaction, (+), scanty reaction, +, weak reaction, ++, moderate reaction, +++, strong reaction. The stained sections were photographed with a Leitz Aristoplan microscope (Wetzlar, Germany).

In order to further characterise the localisation of the protein adducts, double-immunostaining of liver sections for the protein adducts and different cell type-specific marker proteins were performed using an indirect immunofluorescence technique and dual staining techniques. The steps in the immunostainings were essentially the same as described earlier by Niemelä et al. (15). The following primary antibodies were used: polyclonal anti-acetaldehyde adduct antiserum diluted 1:50 in 1% BSA-PBS, monoclonal anti-monocytes/macrophages, clone ED-1 (50 μg in 1 ml 1% BSA-PBS), monoclonal anti-desmin, clone DE-U-10 (1:20 in 1% BSA-PBS), and monoclonal anti-α-smooth muscle actin, clone 1A4 (1:200 in 1% BSA-PBS). The second antibodies were fluorescein isothiocyanate (FITC)-conjugated swine anti-rabbit IgG (Dakopatts) and tetramethylrhodamine isothiocyanate (TRITC)-conjugated goat anti-mouse IgG (Dakopatts) diluted 1:30 and 1:100 in 1% BSA-PBS, respectively. After immunostaining, the sections were mounted in FluoroGuard (Bio-Rad Laboratories, Hercules, CA, USA) and viewed using a confocal laser-scanning microscope (Leitz CLSM, Leica Laser Technics, Heidelberg, Germany).

Statistics

The values are expressed as mean±SD. The differences were considered significant at $p<0.05$. Spearman's rank correlation test was used to calculate correlations between the different variables. The abbreviation r_s stands for the correlation coefficient for the Spearman's rank correlation test.

Results

Characteristics of the study groups

The weights of the animals fed the control diet or the acetaldehyde-containing diet were not different. The

PM3006739376

Source: https://www.industrydocuments.ucsf.edu/docs/psnx0001

TABLE 1

Histological and clinical characteristics of the experimental animals after 11 weeks of acetaldehyde administration

	Acetaldehyde adducts (Staining intensity)	Histology		Enzymes	
		pp(%)	pc(%)	AST (U/l)	ALT (U/l)
Acetaldehyde treated					
A1	++	88	24	111	54
A2	++	93	37	171	59
A3	−	89	33	154	50
A4	++	89	54	170	46
A5	+	93	41	163	40
A6	−	85	20	110	56
A7	++	77	16	182	55
A8	++	79	62	179	60
A9	+	80	18	206	44
A10	+	80	33	183	55
Mean±SD	1.3±0.8	85.3±6.0	33.8±15.4	162.9±30.9	51.9±6.7
Control animals					
C1	−	78	18	114	46
C2	(+)	49	6	145	63
C3	−	77	16	158	72
C4	−	73	21	136	57
C5	−	10	0.2	129	35
C6	−	1.6	0.2	120	55
C7	−	6.6	1.4	153	42
C8	(+)	31	7.4	154	42
C9	−	7	0.4	213	45
C10	−	24	7.6	212	55
Mean±SD	0.1±0.2	35.7±31.1	7.8±7.9	153.4±34.4	51.2±11.2

++, strong reaction; +, moderate reaction; (+) weak reaction; −, no reaction.
Hepatocytes occupied by fat in periportal (pp) and pericentral (pc) areas of rat livers (expressed in percentages).

liquid intake was similar between the groups. The general health of the experimental animals was good in both groups and no apparent signs of illness could be observed during the experiment. The blood ethanol and acetaldehyde levels in all animals were undetectable. Blood aspartate aminotransferase and alanine aminotransferase levels in the serum of the acetaldehyde fed rats and the rats fed a control diet but not given acetaldehyde were not significantly different (Table 1).

Liver histopathology

Examination of liver histology and Oil Red O staining revealed pericentral lipid accumulation in the livers of the acetaldehyde-fed rats but not in controls. The morphometric analyses of the liver specimens revealed significantly higher amounts of fat in the animals receiving acetaldehyde. Fatty deposits were present in both zone 1 and zone 3 of the hepatic acinus (Table 1).

Aldehyde-protein adducts

Fig. 1 shows the immunohistochemical localisation of acetaldehyde adducts from liver biopsy specimens following acetaldehyde administration in drinking water. Acetaldehyde-fed animals showed a distinct positive reaction for the acetaldehyde-modified epitopes which was predominant in the pericentral region (Fig. 1). However, a sinusoidal staining component was also present. In some animals positive reactions also occurred in zone 1 hepatocytes. The intensity of the staining reaction varied from one animal to another. The individual data of the experimental animals are given in Table 1. There were no apparent correlations between the relative intensities of the acetaldehyde adducts and serum enzyme levels (data not shown). However, a positive correlation was found between the amount of acetaldehyde adducts and fat in the perivenular (r=0.602, p<0.01) or periportal area (r=0.575, p<0.01). In the control animals, no specific staining for acetaldehyde adducts was seen (Fig. 2).

In order to further characterise the sites of acetaldehyde adduct deposition, double immunostaining techniques using antibodies against acetaldehyde adducts and defined non-parenchymal cells were used. Fig. 3 shows the confocal laser scanning microscopy images for acetaldehyde adducts and Kupffer cells (A, B) and for acetaldehyde adducts and stellate cells (C, D). The centrilobular hepatocytes were found to contain the most abundant amounts of acetaldehyde adducts (Fig. 3A–D), whereas only small amounts of adducts were also observed in Kupffer cells (Fig. 3B) and stellate cells (Fig. 3C and 3D), showing a colocalisation with the protein adducts.

PM3006739377

Source: https://www.industrydocuments.ucsf.edu/docs/psnx0001

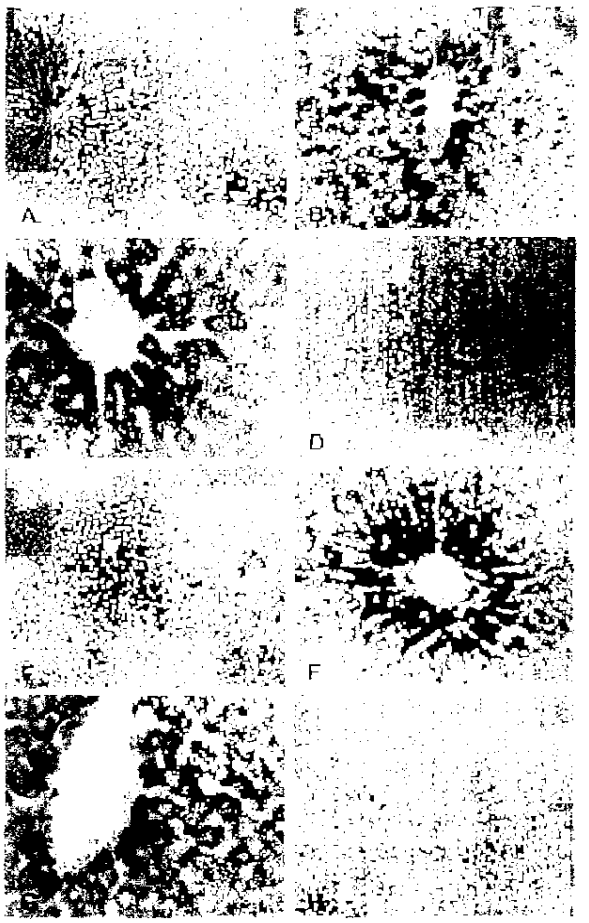

Fig. 1. Immunohistochemical localisation of acetaldehyde-derived epitopes from liver biopsy specimens of rats following acetaldehyde administration in drinking water. Histological examination revealed mild fatty deposition. Positive staining for aldehyde adducts is seen primarily in the centrilobular region. Distinct positive staining also occurred in the periportal region (p) and along the sinusoids (indicated by arrows). A–D: animal no. A1, E–H: animal no. A2. Original magnifications: A, D, E, H: ×100, B, F: ×250, C, G: ×500. Staining with non-immune serum revealed no specific staining (D, H).

Fig. 2. Immunohistochemical staining for acetaldehyde-derived epitopes (A, B, D, E) or non-immune serum (C, F) revealed no specific staining in liver biopsy specimens of control animals. A–C: animal no. C5, D–E: animal no. C6. Original magnifications: A, C, D, F: ×100, B, E: ×250.

Discussion

The present data demonstrate the formation of acetaldehyde-protein adducts in the liver as a result of acetaldehyde administration in drinking water. To our knowledge, this is the first study to show the capability of extrahepatic acetaldehyde to form protein adducts in the liver. Hepatocellular protein adducts were detected concomitantly with fatty change in the same vicinity, suggesting that acetaldehyde originating from extrahepatic sources may play a role in the production of liver lesions. The present data also support a role of covalent binding of acetaldehyde as a mechanism for acetaldehyde toxicity *in vivo*.

Acetaldehyde has previously been shown to form adducts with a variety of individual proteins. Although the primary structures of such condensation products have not been fully established, Tuma and co-workers have previously demonstrated that free ε-aminolysine groups are important targets of adduct formation (16,17). Several proteins with strong reactivity towards aldehydic groups apparently exist *in vivo*, such as albumin (2,18), erythrocyte proteins (2,19), tubulin (20), lipoproteins (8,21), or cytochrome enzymes participating in the metabolism of ethanol (22). As a result of acetaldehyde binding, several adverse functional effects, such as interference with protein function (17,20), stimulation of immunological responses (2,3,23,24) or activation of carcinogenesis (25,26), may be expected to take place. Through adduct formation,

PM3006739378

Source: https://www.industrydocuments.ucsf.edu/docs/psnx0001



Fig. 3. Identification of acetaldehyde adduct-positive cells in liver sections from acetaldehyde-fed rats using double immunofluorescence staining for AA adducts (FITC, green colour) and cell type-specific marker proteins (TRITC, red colour). Panels A–D show that the signal for acetaldehyde adducts is most prominent in the hepatocytes, the staining intensity being highest in close proximity to the central vein (cv). The sections in panels A and B were double immunostained using anti-AA adduct and ED1 antibodies. Arrows in panel B demonstrate the Kupffer cells which are positively stained for acetaldehyde adducts. In panel C, quiescent stellate cells (arrows) visualised using anti-desmin antibody are predominantly negative for acetaldehyde adducts. Yellow colour indicates positive signal in occasional stellate cells. In panel D, activated stellate cells (arrows) identified using anti-α-smooth muscle actin also remain mainly negative for acetaldehyde adducts. Bars: 20 μm.

acetaldehyde also stimulates lipid peroxidation (27) and fibrogenesis (28,29).

Previously, in experimental animals the appearance of hepatic aldehyde adducts has been demonstrated as a result of chronic ethanol intake in connection with increased serum aminotransferase levels, accumulation of fat and signs of hepatocellular injury (6,7,15,30,31). Several studies have also demonstrated acetaldehyde adducts in human patients with alcoholic liver disease (4,5,15). In the present experiments, increased accumulation of fat was the only histological alteration, whereas there were no enzyme elevations as a result of acetaldehyde administration. While the mechanisms for the fat accumulation remain unclear, it should be noted that the present study shows a correlation between the deposition of fat and the amount of acetaldehyde adducts. Interestingly, generation of reducing equivalents (which also favours adduct formation) under conditions of high level expression of alcohol dehydrogenase (ADH) was recently shown to result in a significant accumulation of fat (32). The severity of steatosis has in turn been shown to correlate with hepatic stellate cell activation and induction of fibrogenesis even in the absence of necroinflammatory changes in alcoholic liver disease (33). It should also be noted that acetaldehyde may in fact prevent nuclear factor kappa B activation and hepatic inflammation in ethanol-fed rats (34).

The degree of liver protein modification by acetaldehyde has recently been shown to correlate with liver injury also in ethanol-fed rats (35). In contrast to the present findings, acetaldehyde generated in the metabolism of ethanol appears, however, to result in the generation of markedly smaller amounts of protein adducts (15,31), which also show a more striking perivenular distribution. The centrilobular region is also known to contain the most abundant amounts of ethanol-metabolising enzymes (1,36,37). In ALD, fat also accumulates preferentially in zones 3 and 2 of the hepatic acinus. There is, however, considerable variation in the zonal distribution of fat, which is of limited value in distinguishing the fatty change of alcoholic liver disease from that seen in other disease states (38). In the present work the centrilobular hepatocytes were found to contain the most abundant amounts of protein adducts, although Kupffer cells and stellate cells also contained small amounts of colocalising protein adducts. Interestingly, previous studies by Holstege and co-workers have shown the occurrence of sinusoidal acetaldehyde adducts, which were further shown to correlate with the prognosis of human alcoholic patients (5). Taken together, the present and previous observations support the possibility of extrahepatic acetaldehyde in generating perhaps more toxic effects and more widespread distribution of adducts in the liver than acetaldehyde generated inside the hepatocytes during ethanol metabolism.

It has been previously well established that relatively large quantities of acetaldehyde may be produced by colonic microbes (9–11,13,39). This intracolonically produced acetaldehyde has been suggested to play an important role in the pathogenesis of ALD. Previous observations on humoral IgA isotype immune responses against acetaldehyde-modified proteins also support the possibility that acetaldehyde-derived antigenic epitopes may be of intestinal origin (3,23,24), since IgA antibodies are known to be readily generated upon intestinal antigenic stimulation (40). In accordance with this view the existence of acetaldehyde ad-

PM3006739379

Source: https://www.industrydocuments.ucsf.edu/docs/psnx0001

ducts on the cell surface, as noted in several previous studies (5,41–44), may also originate in part from acetaldehyde generated by colonic microbes in the digestive tract.

In addition to the acetaldehyde produced by colonic bacteria, evidence has accumulated to indicate that extrahepatic acetaldehyde formation may also take place during ethanol oxidation in the stomach (1,45–47). Although theoretically acetaldehyde delivered in drinking water could also be transformed to ethanol by ADH in the digestive tract, it should be noted that blood ethanol concentrations in the portal blood after acetaldehyde administration have been shown to be negligible after peroral administration of acetaldehyde (12), which may be due to the high Km values of the gastrointestinal isoenzymes. Nevertheless, since acetaldehyde is a highly reactive compound, future studies are warranted to address the possibility that acetaldehyde adducts could also be deposited in the stomach and upper gastrointestinal tract.

In conclusion, the present data indicate that administration of acetaldehyde in drinking water results in the production of histological abnormalities and large quantities of protein-acetaldehyde adducts in the liver. Such mechanisms may contribute to liver damage associated with extrahepatic pathways of ethanol oxidation.

Acknowledgements

The expert assistance of Mrs Lissu Hukkanen and Mrs Katja Viitala is gratefully acknowledged.

This study was supported by grants from the Finnish Foundation for Alcohol Studies.

References

1. Lieber CS. Medical disorders of alcoholism. N Engl J Med 1995; 333: 1058–65.
2. Israel Y, Hurwitz E, Niemelä O, Arnon R. Monoclonal and polyclonal antibodies against acetaldehyde-containing epitopes in acetaldehyde-protein adducts. Proc Natl Acad Sci USA 1986; 83: 7923–7.
3. Tuma DJ, Klassen LW. Immune responses to acetaldehyde-protein adducts: role in alcoholic liver disease. Gastroenterology 1992; 103: 1969–73.
4. Niemelä O, Juvonen T, Parkkila S. Immunohistochemical demonstration of acetaldehyde-modified epitopes in human liver after alcohol consumption. J Clin Invest 1991; 87: 1367–74.
5. Holstege A, Bedossa P, Poynard T, Kollinger M, Chaput JC, Houglum K, et al. Acetaldehyde-modified epitopes in liver biopsy specimens of alcoholic and nonalcoholic patients: localization and association with progression of liver fibrosis. Hepatology 1994; 19: 367–72.
6. Yokoyama H, Nagata S, Moriya S, Kato S, Ito T, Kamegaya K, et al. Hepatic fibrosis produced in guinea pigs by chronic ethanol administration and immunization with acetaldehyde adducts. Hepatology 1995; 21: 1438–42.
7. Niemelä O, Parkkila S, Ylä-Herttuala S, Villanueva J, Ruebner B, Halsted CH. Sequential acetaldehyde production, lipid peroxidation and fibrogenesis in micropig model of alcohol-induced liver disease. Hepatology 1995; 22: 1208–14.
8. Lin RC, Dai J, Lumeng L, Zhang M. Serum low density lipoprotein of alcoholic patients is chemically modified *in vivo* and induces apolipoprotein E synthesis by macrophages. J Clin Invest 1995; 95: 1979–86.
9. Jokelainen K, Roine RP, Väänänen H, Salaspuro M. *In vitro* acetaldehyde formation by human colonic bacteria. Gut 1994; 35: 1271–4.
10. Jokelainen K, Matysiak-Budnik T, Mäkisalo H, Höckerstedt K, Salaspuro M. High intracolonic acetaldehyde values produced by a bacteriocolonic pathway for ethanol oxidation in piglets. Gut 1996; 39: 100–4.
11. Salaspuro M. Bacteriocolonic pathway for ethanol oxidation. Alcohol Clin Exp Res 1998; 22: 772–3.
12. Matysiak-Budnik T, Jokelainen K, Kärkkäinen P, Mäkisalo H, Ohisalo J, Salaspuro M. Hepatotoxicity and absorption of extrahepatic acetaldehyde in rats. J Pathol 1996; 178: 469–74.
13. Salaspuro M. Bacteriocolonic pathway for ethanol oxidation: characteristics and implications. Ann Med 1996; 28: 195–200.
14. Jokelainen K, Heikkonen E, Roine R, Lehtonen H, Salaspuro M. Increased acetaldehyde production by mouthwashings from patients with oral cavity, laryngeal, or pharyngeal cancer. Alcohol Clin Exp Res 1996; 20: 1206–10.
15. Niemelä O, Parkkila S, Ylä-Herttuala S, Halsted C, Witztum JL, Lanca A, et al. Covalent protein adducts in the liver as a result of ethanol metabolism and lipid peroxidation. Lab Invest 1994; 70: 537–46.
16. Tuma DJ, Newman MR, Donohue TM, Sorrell MF. Covalent binding of acetaldehyde to proteins: participation of lysine residues. Alcohol Clin Exp Res 1987; 11: 579–84.
17. Mauch TJ, Donohue TM, Zettermann RK, Sorrell MF, Tuma DJ. Covalent binding of acetaldehyde selectively inhibits the catalytic activity of lysine dependent enzymes. Hepatology 1986; 6: 263–9.
18. Donohue TM, Tuma DJ, Sorrell MF. Acetaldehyde adducts with proteins: binding of [^{14}C] acetaldehyde to serum albumin. Arch Biochem Biophys 1983; 220: 239–76.
19. Hernández-Muñoz R, Baraona E, Blacksberg I, Lieber CS. Characterization of the increased binding of acetaldehyde to red blood cells in alcoholics. Alcohol Clin Exp Res 1989; 13: 654–9.
20. Smith SL, Jennett RB, Sorrell MF, Tuma DJ. Acetaldehyde substoichiometrically inhibits bovine neurotubulin polymerization. J Clin Invest 1989; 84: 337–41.
21. Wehr A, Rodo M, Lieber CS, Baraona E. Acetaldehyde adducts and autoantibodies against VLDL and LDL in alcoholics. J Lipid Res 1993; 34: 1237–44.
22. Behrens UJ, Hoerner M, Lasker JM, Lieber CS. Formation of acetaldehyde adducts with ethanol-inducible P450IIE1 *in vivo*. Biochem Biophys Res Commun 1988; 154: 584–90.
23. Worrall S, de Jersey J, Shanley BC, Wilce PA. Antibodies against acetaldehyde-modified epitopes: an elevated IgA response in alcoholics. Eur J Clin Invest 1991; 21: 90–5.
24. Viitala K, Blake JE, Israel Y, Niemelä O. Serum IgA, IgG, and IgM antibodies directed against acetaldehyde-derived epitopes: relationship to liver disease severity and alcohol consumption. Hepatology 1997; 25: 1418–24.
25. Fraenkel-Konrad J, Singer G. Nucleoside adducts are formed by cooperative reaction of acetaldehyde and alcohols: a possible mechanism for the role of alcohol in carcinogenesis. Proc Natl Acad Sci USA 1988; 85: 3959–61.
26. Homann N, Kärkkäinen P, Koivisto T, Nosova T, Jokelainen K, Salaspuro M. Effects of acetaldehyde on cell regeneration and differentiation of the upper gastrointestinal tract mucosa. J Natl Cancer Inst 1997; 89: 1692–7.
27. Cederbaum AI. Role of lipid peroxidation and stress in alcohol toxicity. Free Rad Biol Med 1989; 7: 537–9.
28. Moshage H, Casini A, Lieber CS. Acetaldehyde selectively stimulates collagen production in cultured rat liver fat-storing cells but not in hepatocytes. Hepatology 1990; 12: 511–8.

PM3006739380

Source: https://www.industrydocuments.ucsf.edu/docs/psnx0001

29. Pares A, Potter JJ, Rennie L, Mezey E. Acetaldehyde activates the promoter of the mouse α2(I) collagen gene. Hepatology 1994; 19: 498–503.
30. French SW, Wong K, Jui L, Albano E, Hagbjörk A-L, Ingelman-Sundberg M. Effect of ethanol on cytochrome P450 (*CYP2E1*), lipid peroxidation and serum protein adduct formation in relation to liver pathology pathogenesis. Exp Mol Pathol 1993; 58: 61–75.
31. Niemelä O, Pasanen M, Parkkila S, Iimuro Y, Bradford B, Thurman RG. Early alcoholic liver injury formation of protein adducts with acetaldehyde and lipid peroxidation products, and expression of *CYP2E1* and *CYP3A*. Alcohol Clin Exp Res 1998; 22: 2118–24.
32. Galli A, Price D, Crabb D. High-level expression of rat class I alcohol dehydrogenase is sufficient for ethanol-induced fat accumulation in transduced HeLa cells. Hepatology 1999; 29: 1164–70.
33. Reeves HL, Burt AD, Wood S, Day CP. Hepatic stellate cell activation occurs in the absence of hepatitis in alcoholic liver disease and correlates with the severity of steatosis. J Hepatol 1996; 25: 677–83.
34. Lindros KO, Jokelainen K, Nanji AA. Acetaldehyde prevents nuclear factor-kappa B activation and hepatic inflammation in ethanol-fed rats. Lab Invest 1999; 79: 799–806.
35. Li CJ, Nanji AA, Siakotos AN, Lin RC. Acetaldehyde-modified and 4-hydroxynonenal-modified proteins in the livers of rats with alcoholic liver disease. Hepatology 1997; 26: 650–7.
36. Kato S, Ishii H, Aiso S, Yamashita S, Ito D, Tsuchiya M. Histochemical and immunohistochemical evidence for hepatic zone 3 distribution of alcohol dehydrogenase in rats. Hepatology 1990; 12: 66–9.
37. Tsutsumi M, Lasker JM, Shimizu M, Rosman AS, Lieber CS. The intralobular distribution of ethanol inducible P450IIE1 in rat and human liver. Hepatology 1989; 10: 437–46.
38. Review by an International Group. Alcoholic liver disease: morphological manifestations. Lancet 1981; i: 707–11.
39. Visapää J-P, Jokelainen K, Nosova T, Salaspuro M. Inhibition of intracolonic acetaldehyde production and alcoholic fermentation in rats by ciprofloxacin. Alcohol Clin Exp Res 1998; 22: 1161–4.
40. Kerr MA. The structure and function of human IgA. Biochem J 1990; 271: 285–96.
41. Lin RC, Sidner RA, Fillenwarth MJ, Lumeng L. Localization of protein-acetaldehyde adducts on cell surface of hepatocytes by flow cytometry. Alcohol Clin Exp Res 1992; 16: 1125–9.
42. Thiele GM, Miller JA, Klassen LW, Tuma DJ. Long-term ethanol administration alters the degradation of acetaldehyde adducts by liver endothelial cells. Hepatology 1996; 24: 643–8.
43. Trudell JR, Ardies CM, Green CE, Allen K. Binding of anti-acetaldehyde IgG antibodies to hepatocytes with an acetaldehyde-phosphatidylethanolamine adduct on their surface. Alcohol Clin Exp Res 1991; 15: 295–9.
44. Paradis V, Scoazec JY, Köllinger M, Holstege A, Moreau A, Feldmann G, et al. Cellular and subcellular localization of acetaldehyde-protein adducts in liver biopsies from alcoholic patients. J Histochem Cytochem 1996; 44: 1051–7.
45. Frezza M, Di Padova C, Pozzato G, Terpin M, Baraona E, Lieber CS. High blood alcohol levels in women. The role of decreased gastric alcohol dehydrogenase activity and first pass metabolism. N Engl J Med 1990; 322: 95–9.
46. Salmela KS, Sillanaukee P, Itälä L, Väkeväinen S, Salaspuro M, Roine RP. Binding of acetaldehyde to rat gastric mucosa during ethanol oxidation. J Lab Clin Med 1997; 129: 627–633.
47. Seitz HK, Gartner U, Egerer G, Simanowski UA. Ethanol metabolism in the gastrointestinal tract and its possible consequences. Alcohol Alcohol 1994; 2: 157–62.

PM3006739381

Source: https://www.industrydocuments.ucsf.edu/docs/psnx0001